

Case study about de Quervain`s tenosynovitis – Jimmy Boharfa

Medical and social history:

Young woman, 35 years old. She works as a hairdresser. Married with 2 small children, twins at the age of 11 months. Previously no bodily pains, except from some shoulder and neck pain after working long days in her salon. No known diseases from earlier. No known traumas. No prescription medication taken daily. No known hereditary diseases of the family. Right-handed.

Referral:

Patient was referred to me from her general practitioner because of pain and swelling over the right radial distal wrist. The pain began about 6 months ago. X-rays are taken, with negative results of pathology. The patient has tried NSAIDS for 4 weeks without effect. The pain has gradually escalated. Now she has a sharp pain in the right wrist, which is aggravated by the movements of the wrist and thumb. A slight numbness in her thumb and index finger. VAS from 30 to 80, depending on movement and weight of the activity performed with right hand. The patient's pain inhibits her in work and leisure. She is having trouble lifting and helping her children. She has been sick leaved from her work as a hair dresser for 4 weeks, but this has not given any improvement in pain.

Clinical examination:

Neurological examination upper extremities without notice.

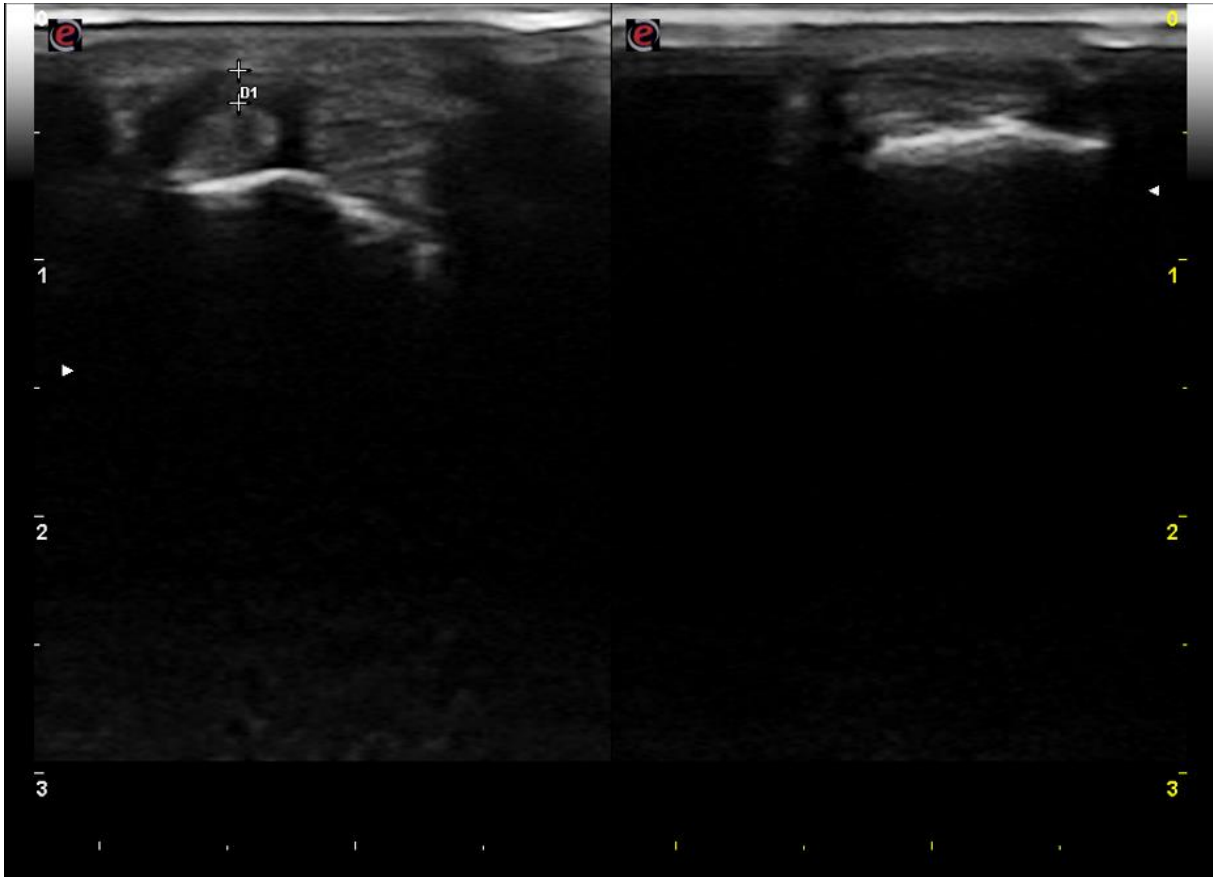
Finkelstein`s test is positive right hand. WHAT-test is positive right hand.

Palpation sore over the right radius process styloid and the 1st dorsal compartment of extensors, pain with resisted abduction of the right thumb.

Ultrasound examination:

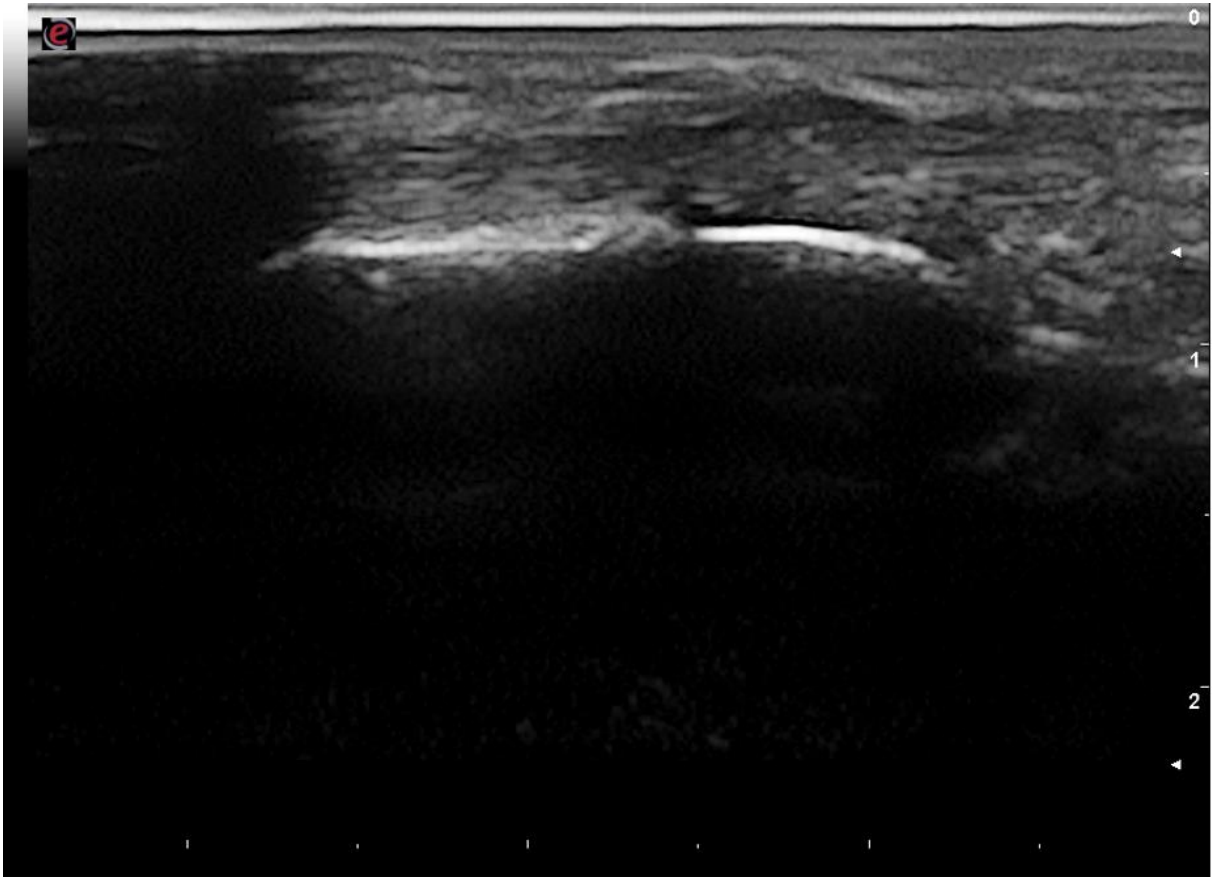
Transverse view above 1. dorsal extensor compartment, bilateral for comparison.

It is seen a hypoechoic thickening of the tendon sheath of the 1. dorsal compartment with a normal-looking tendon without accumulation of fluid. No septum is seen between abductor pollicis longus and extensor pollicis brevis tendons.



Longitudinal view above the extensors in the 1st dorsal compartment.

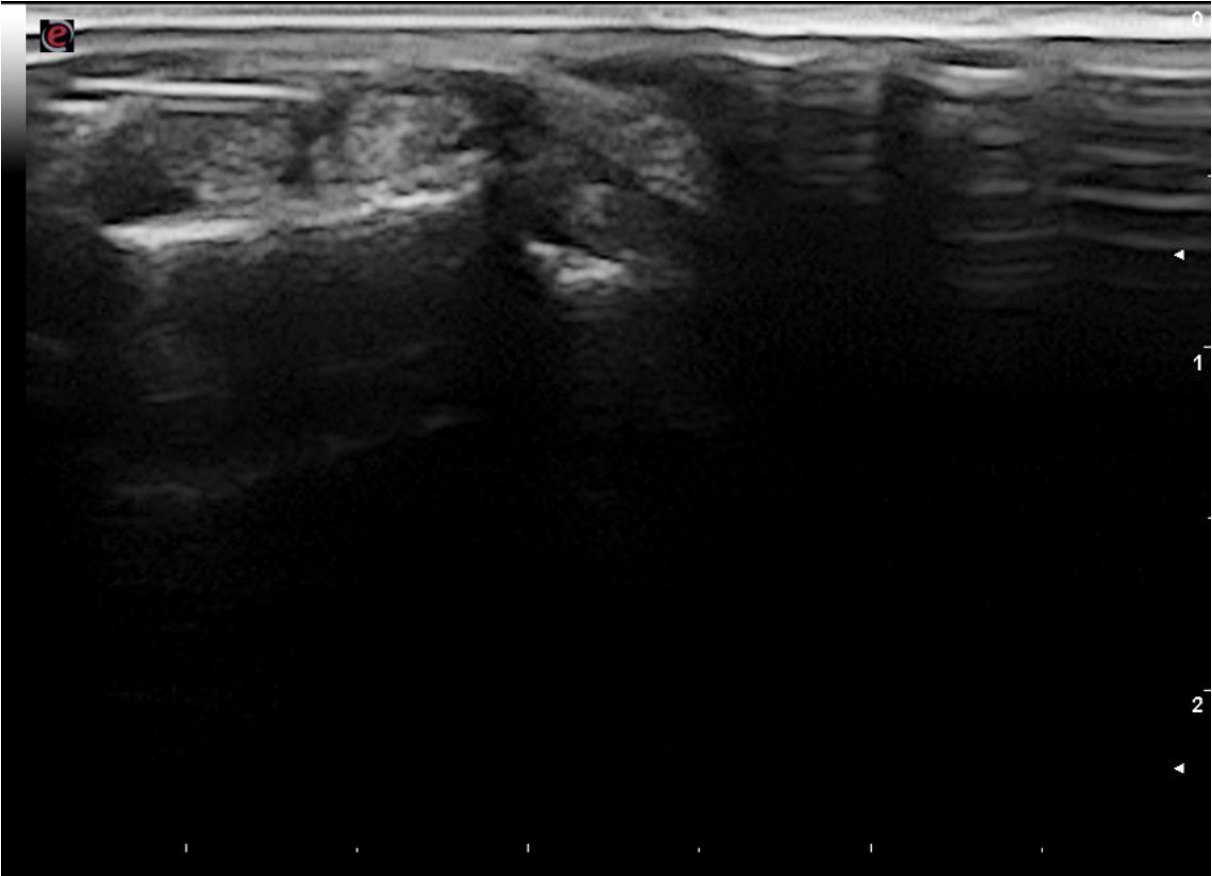
The thickening of the tendon sheet is found in longitudinal view proximal to the radial process styloid.

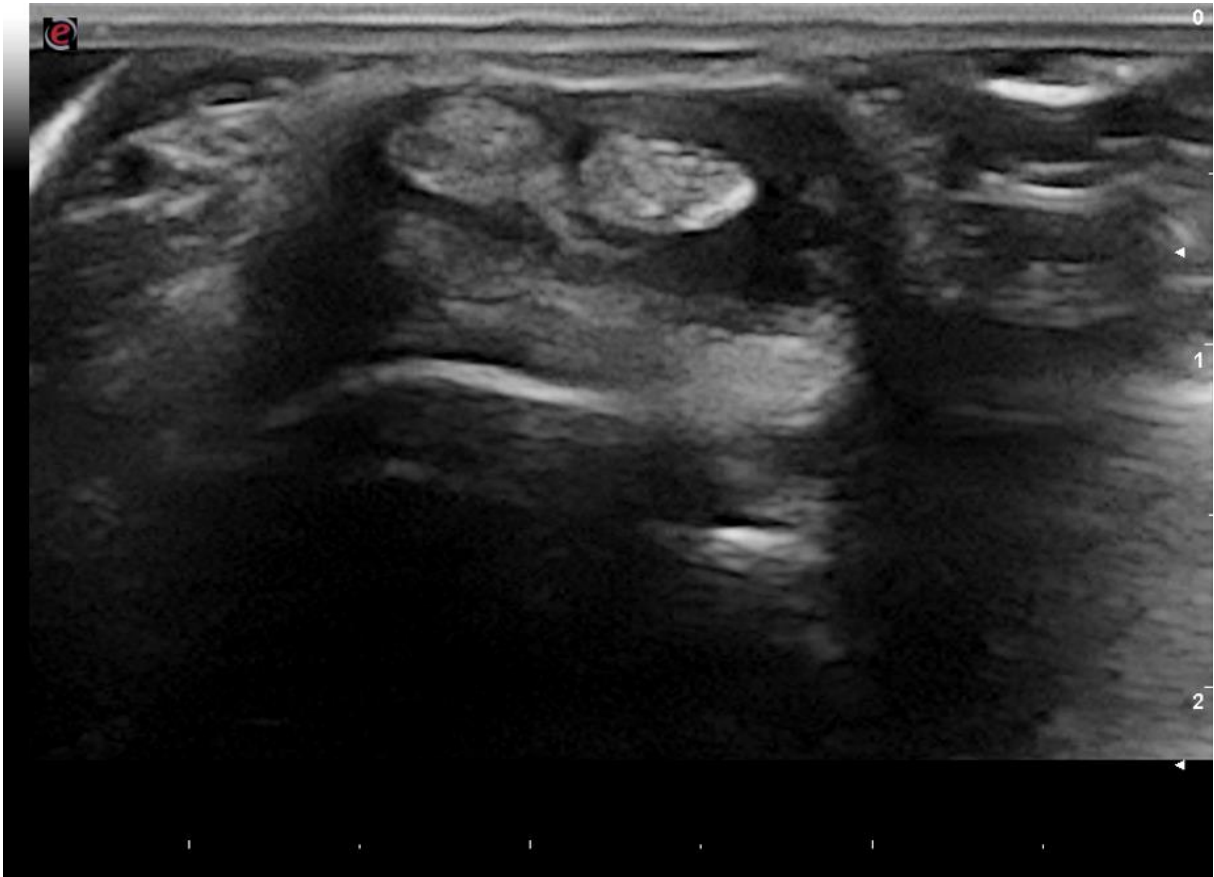


Interpretation of ultrasound and clinical findings:

Clinical and ultrasound examination and findings confirms the diagnosis of De Quervain's Tenosynovitis.

Treatment:





The patient got a consent form with information about procedure and potential risks and adverse reaction at the last visit to the clinic. The patient is sitting on the treatment couch with her right hand nearest to the ultra sound machine, facing the clinician. Her hand is resting at a small pillow. The patient is informed and has understood her rights to say no to the treatment, has given her consent, is advised to keep her hand in rest for about two weeks after the injection, and the possible risks around the procedures.

The patient is treated with 10 milligrams of depomedrone injection together with 1 ml of 2% lidocaine and 1 ml of salin.

The injection is carried out with a 5 ml syringe, 23 G 1 inch needle.

The patient wrist is washed with chlorexidine, transducer cover is used, as well as sterile ultra sound gel, to minimize the risk of a local infection. The clinician is also using sterile gloves and face mask.

Nerves and vessels are localized to be avoided before injection.

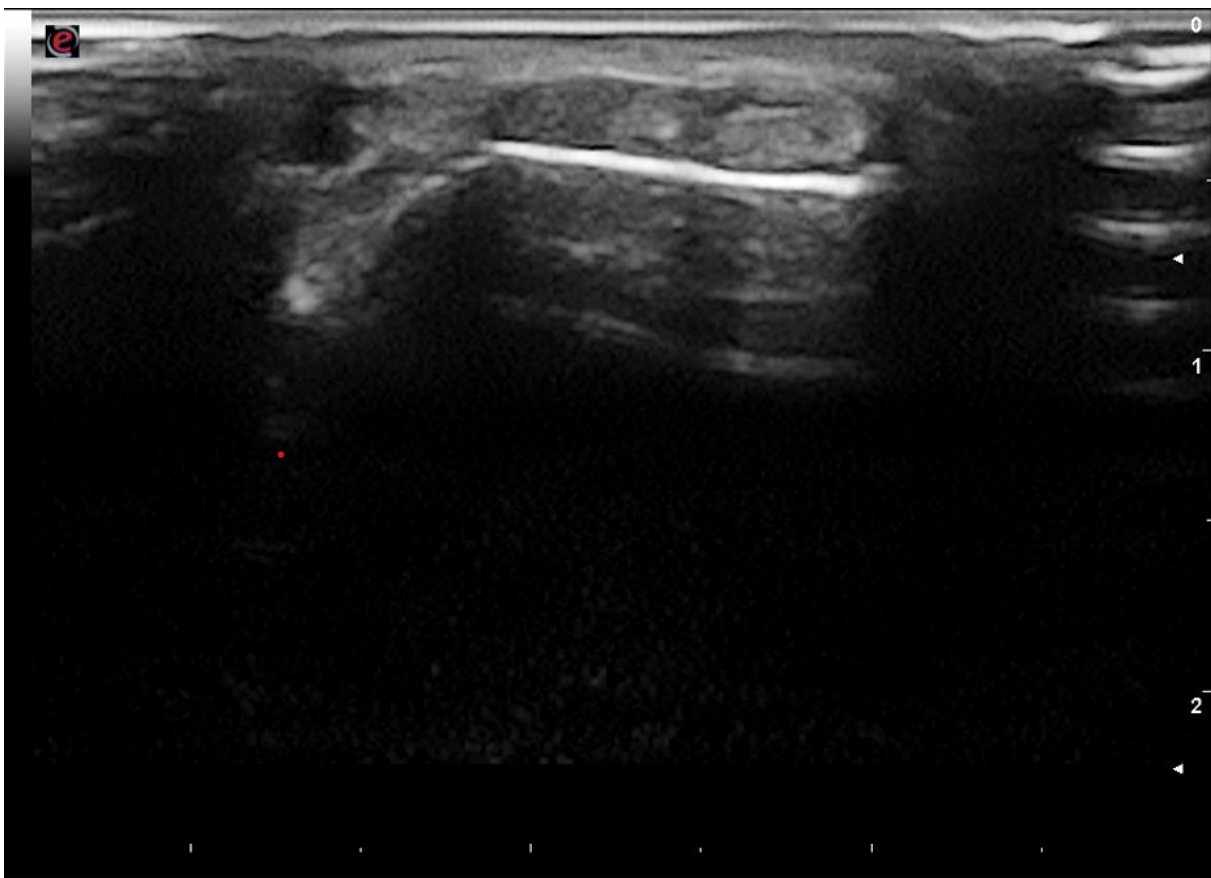
The injection is carried out in plane transverse incision from palmarside.

Aspiration before injection is carried out to ensure to not inject vessels. Ultra sound during injection is done to avoid penetration of the vessels and nerves, and to see that the medicine is placed around the tendon. It shows that the injectate encircles the tendon fully.

Finkelsteins test is performed and pain free after the injection. The patient is placed in a room for observation for 20 minutes after the injection. She gets information about swelling, rubor and fever are signs of an infection after injection, and that she hve to contact her general practicinor if this happens.

Follow up:

Control after six weeks:



The patient is symptom free, no side effects of the injection. Finkelstein test and WHAT-test is negative. VAS has subsided to 0 to 10, depending on what activity she is doing. The extensor pollicis brevis and abductor pollicis longus tendons are sliding nicely, without problems, inside the tendon sheath.

When scanning with ultrasound over the 1st extensor compartment, a normal tendonsheet without thickening is seen.

The patient has been offered a follow up injection if symptoms worsens again. She is coming back in for a new control in six months.

History of De Quervain`s disease

De Quervain`s was first described in the literature in 1893, by doctor Paul Jules Tillaux. Surgeon Fritz de Quervain, from where the disease got its name, found tenosynovitis on a woman with pain in her wrist in 1894. (Jenson Mak, 2018). De Quervain`s tenosynovitis is the most common cause of tendinopathy in the hand in the adult population, with only trigger finger more common. (Jenson Mak, 2018)

Biomechanics and pathophysiology:

In patients with De Quervain`s tenosynovitis, there is an increased cellular matrix and disorganization of collagen which is the most common histopathological finding. Still, there can be found inflammatory cells within the tendon sheath, seen in microscopes (Clarke et al,1998).

De Quervain's tenosynovitis is causing problems with the gliding of the abductor pollicis longus and extensor pollicis brevis, because the synovial sheet of these tendons is narrowed. It is normally caused by repetitive movements of the wrist and thumb (Pooswamy & Muralidharaogpalan, 2019).

Inflammation and edema can often be seen in patients with De Quervain`s disease. This is believed to be due to thickening of the extensor retinaculum, who holds the abductor pollicis

longus and extensor pollicis brevis tight to the process styloid of radius in a fibro osseous tunnel, can cause problems with the gliding of the tendon within the tunnel. In about or more than 10 % of the patients with symptoms of De Quervain`s, an intertendinous septum can be found between the abductor pollicis longus and extensor pollicis brevis. If this septum is present, there is a high chance that the patient needs surgical management to get rid of the pain (Stahl et al, 2013)

Risk factors for De Quervains disease

Pregnancy is a risk factor for De Quervain`s disease, together with motherhood and menopause (Vuillemin et al., 2012). It is more common by women than men, to be a female double or more than doubles the risk to get De Quervain`s (Wolf, Sturdivant & Owens, 2009). Over use of the wrist and fore arm are however is the main contributor for De Quervain`s disease (Stahl et al, 2015). The chance of getting De Quervains increase if you are nonwhite, and if you are more than 40 years (Wolf, Sturdivant & Owens, 2009). If you have a divided septum in the first extensor compartment, or multiple slips of the extensor pollicis longus, you will also have a higher risk of getting De Quervains disease (Mansur et al, 2010)

Diagnosis of De Quervain`s disease

Clinical examination:

Finkelstein test:

Harry Finkelstein first described the Finkelstein test in 1930. If a sharp pain occurs on the medial site on the distal thumb and radius by deviating the patient`s hand in ulnar direction with a grasp around the patient`s thumb, it is likely to be De Quervain`s tenosynovitis.

The Eichhoff`s test:

The patient makes a fist with her thumb inside the fingers. The therapist stabilizes the forearm and deviates the wrist of the patient to the ulnar side. If the patient presents a pain over the

base of the thumb or the medial site of the under arm, the test indicates tenosynovitis (Goubau et al, 2014). The Finkelstein`s test is more accurate than Eichhoff`s test (Wu, Raipura & Sandher, 2018).

WHAT test (the wrist hyperflexion and abduction of the thumb test):

The WHAT test (wrist hyperflexion and abduction of the thumb) has a greater specificity and sensitivity, compared to the Eichhoff`s test (Goubau et al, 2014), regarding diagnosing De Quervain`s.

Radiology in De Quervain`s:

X-ray:

May show swelling over the process styloid of the radius.

May show periosteal reactions, erosion or sclerosis of the process styloid of the radius.

However, this is not a gold standard radiological examination with the suspicion of De Quervain`s.

MRI:

Often shows tenosynovitis, tendinosis or longitudinal tendon tear. Good radiological examination to show even early signs of De Quervain`s.

Ultrasound:

Can show thickening of abductor pollicis longus tendon and extensor pollicis brevis tendon over the radius process styloid, fluid in the tendon sheath of the first extensor, thickening of the retinaculum (Lee et al, 2014), thickening of the synovia, halo sign and doppler. Good radiological examination to show pathology of De Quervains, also good at showing any differences in the anatomy of the wrist.

Treatment for De Quervain`s disease

Ultrasound guided corticosteroid injection:

Ultrasound guided corticosteroid injection of De Quervain`s is safe, with a small risk of side effects. It`s also more cost effective and more time effective than surgery. There is a 80-96 %

patient reported pain relief and improved function with lower scores on VAS (Visual Analogue Scale) and DASH (Disability of Arm, Shoulder, & Hand questionnaire) after corticosteroid injections, depending on which studies you are looking at (McDermott et al, 2012)

Ultrasound guided corticosteroid injections is the most effective and common non-surgical procedure for patients with De Quervain`s (Harvey, Harvey and Horsley, 1990). With a trained sonographer and the correct injection technique, it is a safe and effective procedure (Mirzanli et al, 2012). An article from 2007, showed that 90 % of 36 patients were satisfied with the result after corticosteroid injection (Sawaizumi, Nanno & Ito, 2007). A retrospective study found that female sex and body mass index (BMI) over 30 were significantly associated with treatment failure (Jinhee et al, 2017). A review article done in 2108 found only moderate, short-term evidence of effect of corticosteroid injection for De Quervain`s disease (Huisstede et al, 2018).

Side effects that may occur after a corticosteroid injection, extra-articular:

Side effects are rather seldom, but may occur after a corticosteroid injection outside a joint, extra-articular injections. These can include: Major adverse effects: osteomyelitis, cellulitis, ecchymosis, tendon rupture, atrophy of fat around the injection site. Minor side effects: local skin effects, such as atrophy, change of pigmentation or skin defect. Overall skin rash and/or flushing. Disturbed menstrual cycle. Increased pain and/or steroid flare (Brinks et al, 2010). The incidence of major adverse effects was reported from 0 to 5,8 % and of minor adverse effects from 0 to 81 % when looked at 87 studies.

Other non-surgical treatments for De Quervain`s disease:

Immobilization with splint, exercises, acupuncture, PRP injection (plasma rich platelets injections), hyaluronic acid injections, Methotrexate injection, prolotherapy. The effects of these techniques vary.

Surgical treatment of De Quervain`s disease:

If non-surgical and conservative treatment of De Quervain`s fails, it can be necessary to perform a surgical release. It is normally a safe procedure, who can be performed under local anesthetic. The pain relief is told to be between 90-100 %, and it is long lasting (Scheller et al,

2009). However, there can be complications after De Quervain`s surgery, such as subluxation of the tendons, damage of the radial nerve, incomplete release of the compartments or tendon sheath or scar tenderness (Rogozinski & Lourie, 2016).

Conclusion and discussion:

Both MRI and ultrasound are shown to be good diagnostic tools to detect de Quervain`s tenosynovitis. Some of the clinical tests that we have, and the patient`s history is quite efficient to diagnose de Quervain`s itself without radiology. The role of radiology in the treatment of de Quervain`s seems to most important in differential diagnosis, severity of the disease and various forms of anatomical variations that could affect the choice of treatment strategy. The benefit of diagnostic ultrasound is cost and time efficacy compared to MRI, in addition to be an excellent tool in the injection therapy. Ultrasound is well suited for detecting anatomical variations in the wrist, like subcompartments and intertendinous septum. This may be important to see who will benefit more from surgery than corticosteroid injections, and is also information that can be important for the surgeon before surgery. It is also well documented that women more often get de Quervains, and then often during pregnancy and post-partum. Even if there are no strong evidence that MRI can has a negative effect on the fetus, it is generally not a preferred method of examination for pregnant women. Then ultrasound can be a good choice of radiology.

Most of the studies used in this case study, show a benefit of ultrasound guided injections contra blinded injections. There is a much smaller risk of damage to the radial nerve, the tendons, puncture of vessels and arteries and for fat atrophy when ultrasound is used. This, of course, is dependent of the clinician`s experience with this kind of procedures, anatomical knowledge and ultrasound technique and interpretation. Another benefit is that the clinician can see where the pharmaceuticals under the procedure circles the tendon, and how the needle is steered away from other structures that could be damaged. The retinaculum is around 0,5mm thick, and when inflamed up to 2 mm thick. The probability of getting the injectate in the right place, would seem rather small. However, there are evidence that the effect of a blinded injection gives as good or almost as good pain relief as ultrasound guided injections.

References:

- Mak, Jenson (2018) De Quervain`s Tenosynovitis: Effective Diagnosis and Evidence-Based Treatment, <https://www.intechopen.com/chapters/64725>
- Pooswamy,S.S & Muralidharaogpalan, N.R. (2019) Intra sheath corticosteroid injection for De Quervain`s tenosynovitis, International Journal of Research in Orthopaedics
- Stahl, S, Vida, D, Meisner, C, Lotter, O, Rothenberger, J, Schaller, H-E, Stahl, A.S. (2013) Systematic Review and Meta-Analysis on the Work-Related Cause of de Quervain Tenosynovitis, A Critical Appraisal of Its Recognition as an Occupational Disease, Plastic and Reconstructive Surgery
- Vuillemin, V, Guerini, H, Bard, H, Morvan, G. (2012) Stenosing tenosynovitis, Journal of Ultrasound
- Wolf, J.M,Sturdivant, R.X, Owens, B,R. (2009) Incidence of de Quervain's tenosynovitis in a young, active population, The Journal of Hand Surgery
- Stahl,s, Vida, D, Meisner, C, Stahl, A.S, Schaller, H-E, Held, M. (2015) Work related etiology of de Quervain`s tenosynovitis: a case-control study with prospectively collected data., BMC Musculoskeletal Disorders
- Mansur D.I, Krishnamurthy A, Nayak S,R, et al. (2010) Multiple tendons of abductor pollicis longus extensors, Int J Anat Var
- Goubau J.F, Goubau L, Van Tongel A, Kerckhove D, Van Hoonacker P, Berghs B (2015) The wrist hyperflexion and abduction of the thumb (WHAT) test: a more specific and sensitive test to diagnose de Quervain tenosynovitis than the Eichhoff's Test, J Hand Surg Eur
- Wu, F, Rajpura, A, Sandher, D. (2018) Finkelstein's Test Is Superior to Eichhoff's Test in the Investigation of de Quervain's Disease, J Hand Microsurg

Lee, K-H, Kang, C-H, Lee, B.G, Jung, W-S, Kim, D.Y, Lee, C-H. (2014) Ultrasonographic evaluation of the first extensor compartment of the wrist in de Quervain's disease, Journal of Orthopedic Science

McDermott, J.D, Ilyas, A.M, Nazarian, L.N, Leinberry, C.F (2012) Ultrasound-guided injections for de Quervain's tenosynovitis, Clin Orthop Relat Res

Harvey,F.J, Harvey, P.M, Horsley, M.W. (1990) De Quervain's disease: surgical or nonsurgical treatment, J Hand Surg Am

Mirzanli, C, Ozturk, C, et.al (2017) Accuracy of intrasheath injection techniques for de Quervain's disease: a cadaveric study, Journal of Hand Surgery

Brinks, A, Koes, B.W, Volkers, A.C.W, Verhaar, J.A.N, Bierma-Zeinstra, S.M.A (2010) Adverse effects of extra-articular corticosteroid injections: a systematic review, BMC Musculoskeletal Disorders

Scheller, A, Schuh, R, Honle, W, Schuh, A (2009) Long-term results of surgical release of de Quervain's stenosing tenosynovitis, Int Orthop

Rogozinski, B & Lourie, G.M (2016) Dissatisfaction after first dorsal compartment release for de Quervain tendinopathy, The Journal of Hand Surgery

Clarke, M.T, Lyall, H.A, Grant, J.W, Matthewson, M.H. (1998) The Histopathology of De Quervain's Disease, Journal of hand Surgery

Sawaizumi, T, Nanno , M & Ito, H (2007) De Quervain's disease: efficacy of intra-sheath triamcinolone injection, Int Orthop

Jinhee, K et al (2017) Effectiveness of Corticosteroid Injections for Treatment of de Quervain's Tenosynovitis, Hand

Huisstede, B.M, Gladdines, S, Randsdorp, M.S., Koes, B.W (2018) Effectiveness of Conservative, Surgical, and Postsurgical Interventions for Trigger Finger, Dupuytren Disease, and De Quervain Disease: A Systematic Review, Arch Phys Med Rehabil

Huisstede, et al 2018